

PATIENT PRESENTING CLINICAL SIGNS

Felix Reinbold

History: 2/6 murmur

SPECIES ECHOCARDIOGRAPHIC FINDINGS

Feline

2D, M-mode, and Doppler study.

BREED

Left atrial size is normal. The mitral valve is normal. Left ventricular wall thickness is normal. Left ventricular internal dimensions are normal. Left ventricular systolic function is hyperdynamic. The aorta and aortic valve are normal. Right atrial and right ventricular dimensions are normal. The tricuspid valve appears normal. The pulmonary artery and pulmonic valve are normal. No shunting lesions are visualized. No pericardial effusion or cardiac masses are seen.

DSH

SEX

Male Neutered

LA/Ao - 1.46

IVSd - 4.5 mm

LVPWd - 4.3 mm

LVIDd - 12.7 mm

LVIDs - 4.8 mm

AGE

2 years

FS - 62.2%

LVOT - 1.18 m/s

RVOT - 1.19 m/s

WEIGHT

10.3#

ASSESSMENT/RECOMMENDATIONS

Normal echocardiogram

INTERPRETED BY

Keith Blass, DVM, MS, DACVIM

This examination demonstrates no evidence of structural heart disease. While a definitive reason for Felix's murmur was not identified, it's likely that his murmur is functional/innocent in nature, as no flow abnormalities that could result in the development of a pathologic murmur were appreciated in the image set.

IMAGING PERFORMED BY

Rebekah Jakum, CVT ARDMS/RVT

No therapy is recommended based on this exam.

A recheck echocardiogram is recommended if the characteristics of Felix's murmur change, or if other new physical exam and/or clinical abnormalities suggestive of cardiac dysfunction develop.

HOSPITAL NAME

Mill Pond VC

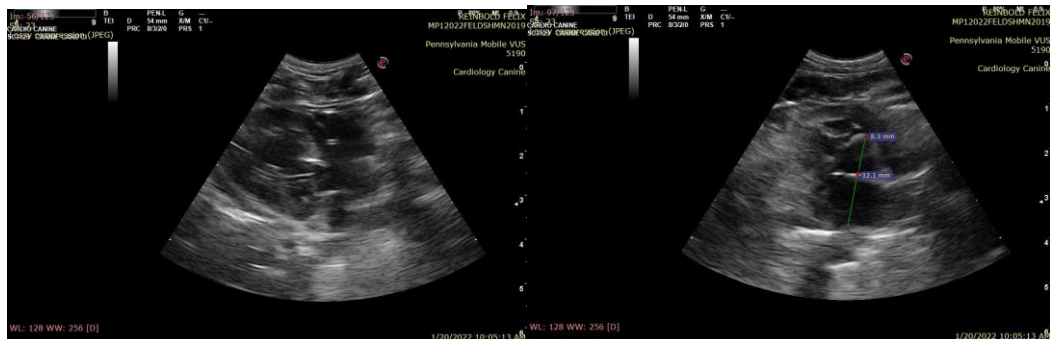REFERRING VET

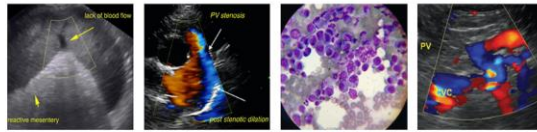
Dr. Loduca

DATE

3/12/17

The information and recommendations provided are based on the images presented by the referring veterinarian. No evaluation can be communicated regarding pathology that was not visible in the





PATIENT image/video clips provided.

Felix Reinbold Thank you for this referral. If the clinical or image interpretation does not parallel your findings or if I can be of any further assistance please contact me.

SPECIES

Feline **Keith Blass, DVM, MS, DACVIM (Cardiology)**

KeithBlass@gmail.com

BREED 631-804-5754

DSH

SEX

Male Neutered

AGE

2 years

WEIGHT

10.3#

INTERPRETED BY

Keith Blass, DVM,
MS, DACVIM

**IMAGING
PERFORMED BY**

Rebekah Jakum, CVT
ARDMS/RVT

HOSPITAL NAME

Mill Pond VC

REFERRING VET

Dr. Loduca

DATE

3/12/17